

Effects of Gelam Honey on Sperm Quality and Testis of Rat (Kesan Madu Gelam ke atas Kualiti Sperma dan Testis Tikus)

N.S. SYAZANA, N.H. HASHIDA*, A.M. MAJID, H.A. DURRIYYAH
SHARIFAH & M.Y. KAMARUDDIN

ABSTRACT

The present study aimed to elucidate the possible protective effects of Gelam honey on sperm quality and testis histology against infertility related problems. Control and treated groups of 4 - 5 weeks old male Sprague-Dawley rats were force-fed daily with 1.0 mL/100 g body weight of normal saline (0.9%) and Gelam honey, respectively. After 60 days of treatments, reproductive organs of the anesthetized rats were removed to assess sperm parameters and histology of testis. Sperm count of treated group was significantly higher ($18.85 \pm 3.72 \times 10^5/\text{mL}$) than control group ($17.05 \pm 3.12 \times 10^5/\text{mL}$) ($p < 0.05$). Based on sperm morphology, treated group showed significantly higher percentage of normal sperm ($96.83 \pm 0.03\%$) as compared to control group ($94.87 \pm 0.01\%$) ($p < 0.01$). Head and tail abnormalities sperm were also significantly reduced in the treated rats ($p < 0.05$). The number of spermatogenic cells in testis of treated group were abundant as compared to control group. Seminiferous tubules of treated group were densely packed with spermatogenic cells with small lumen filled up with sperm tail. This study suggested that Gelam honey has the potential to increase the fertility of male rats by increasing sperm count and number of sperm with normal morphology.

Keywords: Honey; sperm quality; Sprague Dawley rats; testis histology

ABSTRAK

Kajian ini bertujuan untuk menjelaskan kemungkinan kesan pelindung madu gelam ke atas kualiti sperma dan histologi testis terhadap masalah-masalah berkaitan ketidaksuburan. Kumpulan kawalan dan perlakuan bagi tikus Sprague Dawley jantan berumur 4 - 5 minggu, masing-masing disuap-paksa setiap hari dengan 1.0 mL/100 g berat badan salin normal (0.9%) dan madu gelam. Selepas 60 hari tempoh perlakuan, organ pembiakan tikus yang telah dibius dikeluarkan untuk menilai parameter sperma dan histologi testis. Bilangan sperma bagi kumpulan perlakuan adalah lebih tinggi secara signifikannya ($18.85 \pm 3.72 \times 10^5/\text{mL}$) berbanding kumpulan kawalan ($17.05 \pm 3.12 \times 10^5/\text{mL}$) ($p < 0.05$). Keabnormalan kepala dan ekor sperma juga berkurang secara tekal dalam tikus perlakuan ($p < 0.05$). Berdasarkan kepada morfologi sperma, kumpulan perlakuan menunjukkan peratusan sperma normal yang lebih tinggi secara signifikannya ($96.83 \pm 0.03\%$) berbanding dengan kumpulan kawalan ($94.87 \pm 0.01\%$) ($p < 0.01$). Bilangan sel-sel spermatogenik dalam testis kumpulan perlakuan adalah sangat banyak berbanding dengan kumpulan kawalan. Tubul seminiferus kumpulan perlakuan adalah tersusun padat dengan sel-sel spermatogenik dalam lumen yang kecil dipenuhi dengan ekor sperma. Kajian ini menunjukkan bahawa madu gelam mempunyai potensi untuk meningkatkan kesuburan bagi tikus jantan dengan meningkatkan bilangan sperma dan bilangan sperma dengan morfologi normal.

Kata kunci: Histologi testis; kualiti sperma; madu; tikus Sprague Dawley

INTRODUCTION

Environmental, physiological and genetic factors have been shown to have defective effects on male reproductive performance (Plas et al. 2000; Petrelli & Mantovani 2002). Honey with its nutrient rich content, e.g. sugars such as fructose and glucose; minerals such as magnesium, potassium, calcium, sodium chloride, sulphur, iron and phosphates; as well as vitamins B1, B2, C, B6, B5 and B3 (Estevinho et al. 2008), is a candidate of being a reproductive health protection substance. The great Muslim physician, Ibn Sina (980 – 1037) in his world-famous medical textbook ‘The Canon of Medicine’ reported the benefits of honey for treatment of various diseases and maintenance of health (Kamaruddin 1993) and due to its

antibacteria, antioxidant and wound healing properties (Aljady et al. 2000). In Arab countries honey is considered to increase human male potency. It had been reported that honey increased spermatogenesis in rats (Abdul-Ghani et al. 2008). Abdelhafiz and Muhamad (2008) observed *in vitro* that diluted Egyptian bee honey and royal jelly had an enhancing effect on sperm motility, particularly in subnormal samples. Propolis was found to significantly increase testosterone level, body weight, relative weight of testis, relative weight of epididymis, semen characteristics and seminal plasma enzymes and decreased the levels of free radicals and lactate dehydrogenase (Yousef et al. 2010). A preliminary study involving a local Malaysian honey, *Tualang* honey, proposed that honey could enhance

spermatogenesis if given at appropriate dose and also possibly reduced the toxic effect of cigarette smoke on rat spermatogenesis (Mahaneem et al. 2006).

To date, there is a lack of data concerning the medicinal use of honey on reproductive performance and testicular dysfunction. The present study aimed to determine the effects of two months oral administration of Malaysian Gelam honey on sperm quality and histology of testis of rats.

MATERIALS AND METHODS

Eighteen Sprague-Dawley male rats (4-5 weeks old) were randomly divided into two groups. Group 1 rats were forced fed with 1.0 mL/100 g normal saline (0.9%) for control and Group 2 rats with 1.0 mL/100 g Gelam honey for treatment. gelam honey was obtained from the most common Malaysian *Apis mellifera* (*Melaluca cajuputi* spp). The dose of gelam honey was calculated according to animal's body weight on the week of specific treatment. Anesthetized rats were sacrificed and their reproductive organs were removed after 60 days of treatment. The testis weight, length and width were measured. Sperm were collected from cauda epididymis into Toyoda-Yokoyama-Hosi (TYH) medium (Ellis et al. 1985). The sperm suspension was incubated for 1 hour at 37°C under 5% CO₂. The sperm parameters were assessed for sperm count, viability and morphology with 5 replicates for each rat. Sperm morphology and viability were stained with eosin nigrosin staining method (NAFA and ESHRE-SIGA, Laboratory Manual 2002) and observed under light microscope according to the WHO laboratory manual (WHO 1999). Histological processing involved the testes fixed in Bouin's solution prior to being processed with Haematoxylin and Eosin (H&E) staining technique. The experiment was performed in accordance

with the Guidelines for Animal Experiments of the Medical Centre Research Committee, University Malaya [PASUM/16/11/2010/NHH(R)].

Sperm count, viability and morphology between the two groups were compared using PROC TTEST of the Statistical Analysis System (SAS 2006) package. The raw data were first transformed using the square root transformation before being analysed (Steel & Torrie 1980). The assumption that the rats in the two treatment groups were independent of each other was met because different rats were used in each group. The assumption of equal variances were tested by using the Folded *F'* value to test for $H_0: \mu_1 = \mu_2$ against the alternative $H_A: \mu_1 \neq \mu_2$. In the case of equal variances, the two variances were pooled to obtain the *t* value. In the case of unequal variances, the two variances were used in calculating the *t* value (Satterthwaite 1946).

RESULTS

There were no significant differences for weight, length and width of testis between the groups (Table 1). However, sperm count of treated group was significantly higher ($18.85 \pm 3.72 \times 10^5$ /mL) than control group ($17.05 \pm 3.12 \times 10^5$ /mL) ($p < 0.05$). Based on sperm morphology, treated group showed significantly higher percentage of normal sperm ($96.83 \pm 0.03\%$) as compared to control group ($94.87 \pm 0.01\%$) ($p < 0.01$). Lower percentage of abnormal sperm head ($0.77 \pm 0.33\%$) and tail ($2.51 \pm 0.19\%$) were also observed in treated group as compared to control group ($p < 0.05$) (Table 2). Spermatogenic cell layers of control showed less dense packing of spermatogenic cells than the honey treated group. The lumen of control was less densely filled as compared to that of honey treated group which was filled with sperm tail (Figure 1 and 2).

TABLE 1. Morphometric parameters of testis for control and honey treated groups

Treatment Groups	Weight (g) (mean±SEM)	Length (mm) (mean±SEM)	Width (mm) (mean±SEM)
Control (n=9)	1.48±0.03 ^a	20.14±0.29 ^a	12.14±0.07 ^a
Honey treated (n=9)	1.43±0.03 ^a	20.08±0.48 ^a	12.38±0.19 ^a

^asuperscript in the same column shows no significant difference ($p \geq 0.05$)

TABLE 2. Sperm parameters for control and honey treated groups

Parameter	Sperm count ($\times 10^5$) (mean±SEM)	Morphology			Viability	
		Normal (%)	Head abnormalities (%)	Tail abnormalities (%)	Life sperm (%)	Immotile sperm (%)
Control (n=9)	17.05±3.12 ^a	94.87±0.01 ^a	1.33±0.14 ^b	3.39±0.37 ^b	200±0.00 ^a	0.00±0.00 ^a
Gelam honey (n=9)	18.85±3.72 ^b	96.83±0.03 ^b	0.77±0.33 ^a	2.51±0.19 ^a	200±0.00 ^a	0.00±0.00 ^a

^{a,b} superscripts in the same column show significant difference ($p < 0.05$)

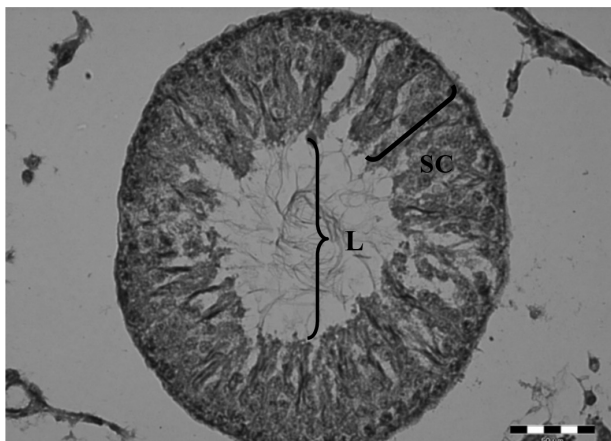


FIGURE 1. Seminiferous tubule of control rat testis showed less dense packing of spermatogenic cells (SC) with wide emptied lumen (L) (scale bar in the photo represent 50 μ m)

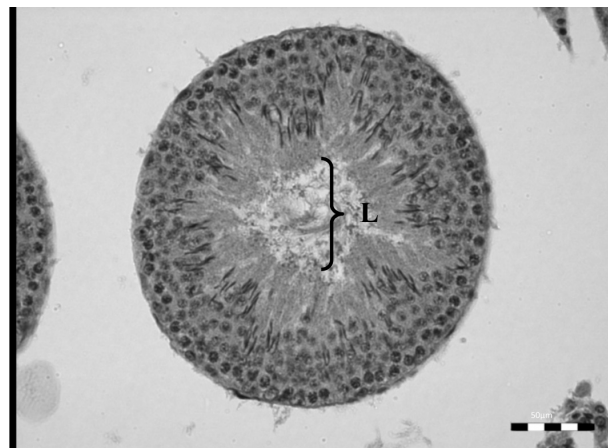


FIGURE 2. Densely packed seminiferous tubule of honey treated rat testis showed small lumen (L) densely filled up with sperm tails (scale bar in the photo represent 50 μ m)

DISCUSSION

Honey represents a natural product with many medicinal applications, including treating male infertility problems. The present results showed no significant difference in the width, length and weight of the testis between control and honey treated groups. This confirms a study by Mahaneem et al. (2006) who observed no significant differences for the percentage of body weight gain and for the absolute and relative weights of testis and male accessory reproductive organs such as prostate, epididymis and seminal vesicles among the groups. However, the present result was in contrast to the observation by Abdul-Ghani et al. (2008) where ingestion of 5% honey for 20 days would induce spermatogenesis in rats by increasing relative weight of the epididymis.

In the present result, several sperm parameters were positively affected by honey. Significantly higher sperm count, higher percentage of normal sperm and lower percentage of sperm head and tail abnormalities were observed in treated group in comparison to control group. Abdul-Ghani et al. (2008) also concluded that honey would induce spermatogenesis in rats by increasing epididymal sperm count and increasing sorbitol dehydrogenase activity. Sorbitol dehydrogenase is an enzyme in carbohydrate metabolism that converts sorbitol, the sugar alcohol form of glucose into fructose (El-Kabbani et al. 2004). Fructose concentration in the seminal plasma has been recommended as a marker of the secretory activity of the seminal vesicles (WHO 1999). Fructose is synthesized by these accessory sex organs under the influence of testosterone and energy for the sperm metabolism and motility (Mann 1964). Honey is also rich with antioxidant polyphenols such as flavonoids and phenolic acids (Gheldof & Engeseth 2002). Antioxidants are main defense against oxygen stress induced by the elevated levels of reactive oxygen

species which affected sperm motility (Said et al. 2004; Sharma & Agarwal 1996).

Although the present study was conducted using local Malaysian gelam honey, the results obtained were similar to that reported by Yousef and Salama (2009) who used propolis. Propolis could provide protection against infertility by improving sperm production, motility, sperm count and quality and increased the process of steroidogenesis and, hence, testosterone production (Yousef & Salama 2009). Royal jelly treatments significantly boosted testosterone level, increased ejaculated volume, increased seminal plasma fructose, improved sperm motility, increased sperm total output, reduced number of abnormal and dead sperm (Elnagar 2010).

Previously, it had been shown that administration of honey at the appropriate dose might enhance the third stage of spermatogenesis in rats (Mahaneem et al. 2007). The histological sections of the current study showed abundant spermatogenic cells which indicated that spermatogenesis was positively facilitated by honey. Probably, honey acts as physiologic modulators of spermatogenic cells proliferation which influence the cell cycle of the seminiferous epithelium thus, increase spermatogenesis. A previous study reported that Sertoli cells play a major role in regulation of spermatogenesis and altering rates of sperm produced (Russell & Griswold 1993). Thus, it is possible that honey could have interacted with Sertoli cells and contributed positively to spermatogenesis. Garner and Hafez (2000) reported that restoration of spermatogenesis could be achieved in the hypophysectomized rat by treatment with both Follicle Stimulating Hormone (FSH) and Luteinizing Hormone (LH). Therefore, further study should be carried out to observe the interaction between honey, concentration of FSH and LH in blood serum, and established the exact mechanism leading to the changes of the spermatogenic cells which involved Sertoli and Leydig cells.

CONCLUSION

Currently, there is a lack of established data concerning the medicinal use of honey in treating infertility of human male. This preliminary study suggested that Gelam honey is potentially useful in increasing the fertility of male rats by increasing sperm count, percentage of normal sperm and reducing the percentage of sperm head and tail abnormalities. However, further works are needed to better understand the beneficial effects of honey on spermatogenesis and also to quantify the histological effects of honey on spermatogenic cells.

REFERENCES

- Abdelhafiz, A.T. & Muhamad, J.A. 2008. Midcycle pericoital intravaginal bee honey and royal jelly for male factor infertility. *International Journal of Gynecology and Obstetrics* 101: 146-149.
- Abdul-Ghani, A.S., Dabdoub, N., Muhammad, R., Abdul-Ghani, R. & Qazzaz, M. 2008. Effect of Palestinian honey on spermatogenesis in rats. *Journal of Medicinal Food* 11(4): 799-802.
- Aljady, A.M., Kamaruddin, M.Y., Jamal, A.M. & Mohd Yassin, M.Y. 2000. Biochemical study on the efficacy of Malaysian honey in infected wounds: An animal model. *Medical Journal of Islamic Academy of Sciences* 13(3): 125-132.
- El-Kabbani, O., Darmanin, C. & Chung, R.P. 2004. Sorbitol Dehydrogenase: Structure, Function and Ligand Design. *Current Medicinal Chemistry* 11(4): 465-476.
- Elnagar, S.A. 2010. Royal jelly counteracts bucks' "summer infertility". *Animal Reproduction Science* 121: 174-180.
- Ellis, D.H., Hartman, T.D. & Moore, H.D.M. 1985. Maturation and function of the hamster spermatozoon probed with monoclonal antibodies. *Journal of Reproductive Immunology*. 7: 299-314.
- Estevinho, L., Pereira, A., Moreira, L., Dias, L. & Pereira, E. 2008. Antioxidant and antimicrobial effects of phenolic compounds extracts of Northeast Portugal honey. *Food and Chemical Toxicology* 46: 3774-3779.
- Garner, D.L. & Hafez, E.S.E. 2000. Spermatozoa and seminal plasma. In *Reproduction in Farm Animals*, edited by Hafez, B. & Hafez, E.S.E. 7th Edition. New York: Lippincott Williams and Wilkins.
- Gheldof, H. & Engeseth, N.J. 2002. Antioxidant capacity of honeys from various floral sources based on the determination of oxygen radical absorbance capacity and inhibition of *in vitro* lipoprotein oxidation in human serum samples. *Journal of Agricultural and Food Chemistry* 50(10): 3050-3055.
- Kamaruddin, M.Y. 1993. Honey: A healing for mankind throughout the ages. *The Fountain* 1(3): 4-6.
- Mahanem, M., Siti Amrah, S., Yatiban, M.K. & Hasnan, J. 2006. Effect of 'Tualang Honey' on Spermatogenesis in Rats. *Proceedings of 1st International Conference on the Medicinal Uses of Honey (from Hive to Therapy)*. Kota Bharu Kelantan, Malaysia.
- Mahaneem, M., Siti Amrah, S., Yatiban, M.K. & Hasnan, J. 2007. Effect of Malaysian honey on the male reproductive system in rats. *The Malaysia Journal of Medical Sciences* 14: 114 (suppl).
- Mann, T. 1964. Metabolism of semen: fructolysis, respiration and sperm energetic. In *The Biochemistry of Semen and the Male Reproductive Tract*. New York: John Wiley and Sons Inc.
- NAFA (Nordic Association for Andrology) and ESHRE (European Society of Human Reproduction and Embryology) – SIGA (Special Interest Group on Andrology). 2002. *Manual on Basic Semen Analysis*.
- Petrelli, G. & Mantovani, A. 2002. Environmental risk factors and male fertility and reproduction. *Contraception* 65: 297-300.
- Plas, E., Berger, P., Hermann, M. & Pflüger, H. 2000. Effects of aging on male fertility. *Experimental Gerontology* 35: 543-551.
- Russell, L.D. & Griswold, M.D. 1993. *The Sertoli Cell*. Clearwater, Florida: Cache River Press.
- SAS. 2006. *Statistical Analysis System Enterprise Guide 4.1*. Cary, North Carolina, USA: SAS Institute.
- Said, T.M., Agarwal, A., Sharma, R.K., Mascha, E., Sikka, S.C. & Thomas, A.J. Jr. 2004. Human sperm superoxide anion generation and correlation with semen quality in patients with male infertility. *Fertility Sterility* 82: 871-877.
- Satterthwaite, F.W. 1946. An approximate distribution of estimates of variance components. *Biom. Bull.* 2:110-114.
- Sharma, R.K. & Agarwal, A. 1996. Role of reactive oxygen species in male infertility. *Urology* 48: 835-850.
- Steel, R.G.D. & Torrie, J.H. 1980. *Principles and Procedures of Statistics: A Biometrical Approach*. USA: McGraw Hill and Company.
- World Health Organization. 1999. *WHO Laboratory Manual for Examination of human Semen and Semen-Cervical Mucus Interaction*. 4th Edition. Cambridge: The Press Syndicate of the University of Cambridge.
- Yousef, M.I. & Salama, A.F. 2009. Propolis protection from reproductive toxicity caused by aluminium chloride in male rats. *Food and Chemical Toxicology* 47: 1168-1175.
- Yousef, M.I., Kamel, K.I., Hassan, M.S. & El-Morsy, M.A. 2010. Protective role of propolis against reproductive toxicity of triphenyltin in male rabbits. *Food and Chemical Toxicology* 48: 1846-1852.

Centre for Foundation Studies in Science
Universiti Malaya
50603 Kuala Lumpur
Malaysia

*Corresponding author; email: nhhpasum@um.edu.my

Received: 25 October 2010

Accepted: 26 April 2011